

Bilateral Vocal Fold Lobular Capillary Hemangioma Mimicking Glottic Carcinoma in a Chronic Smoker

Nur Af'Idah Mohd Zulkefli and Marina Mat Baki*

Department of Otorhinolaryngology-Head and Neck Surgery, Faculty of Medicine, Universiti Kebangsaan Malaysia Medical Centre, Kuala Lumpur, Malaysia

ARTICLE INFO

Article history:

Received: 8 December 2019

Accepted: 11 July 2020

Online:

DOI 10.5001/omj.2021.49

Keywords:

Glottis; Lobular Capillary Hemangioma; Pyogenic Granuloma; Adult; Hoarseness.

ABSTRACT

Laryngeal hemangioma is a rare benign tumor of the larynx with predilection for a supraglottal subsite. Common presentations include hoarseness, dyspnea, and dysphagia, with a typical appearance of a reddish-purple mass. A capillary form of the tumor, lobular capillary hemangioma (LCH) is extremely rare in adults and is predominantly unilateral. Diagnosis is made histologically by the distinct lobular growth pattern of capillary proliferation. Here, we report a 50-year-old male chronic smoker who presented with 3-month history of progressive hoarseness, dry cough, and intermittent dyspnea. Flexible endoscopy of the larynx showed irregular pinkish-white masses on the middle third of the bilateral vocal folds. The provisional diagnosis of glottic carcinoma was ruled out by histopathology, and the final diagnosis was bilateral glottic LCH, making it the first recorded case of this condition in literature. The patient underwent endolaryngeal microsurgery with subepithelial excision, a procedure that can be both diagnostic and therapeutic for this rare tumor.

Laryngeal hemangioma is a rare, benign neoplasm with unknown incidence and etiology.¹ Fechner et al,² classified laryngeal hemangioma into adult and infantile forms, the latter being more common. The proposed etiologies of the adult-form hemangioma include previous laryngeal trauma (e.g., intubation), hormonal shifts (i.e., in pregnancy granuloma), viral oncogenes, infection, and stress.²⁻⁴ The available literature includes only 13 case reports of adult with glottic hemangioma since the first report in 1979, and these were mainly on a unilateral vocal fold.⁵ Here, we present and discuss a rare case of adult bilateral vocal fold hemangioma, which was initially suspected to be a glottic carcinoma in a chronic smoker.

CASE REPORT

A 50-year-old male presented with hoarseness, persistent dry cough, and intermittent dyspnea for three months. The symptoms had progressively worsened for two weeks prior to presentation. The patient had no history of fever, neck swelling, weight loss, night sweat, hemoptysis, contact with tuberculosis (TB) patients, or any laryngopharyngeal

reflux symptoms. A mechanic by trade, the patient was a chronic smoker for 30 years (90 pack years) and used to shout frequently (voice abuse).

The general examination was unremarkable except for the hoarse voice. In the Grade of hoarseness, Roughness, Breathiness, Asthenia, and Strain (GRBAS) Scale,⁶ the patient scored an overall grade 3 (G3, severe hoarseness) with grade 3 roughness (R3). His maximum phonation time (MPT) was short, at seven seconds.

Flexible endoscopy of the larynx revealed an irregular, pinkish mass at the middle third of bilateral true vocal fold. The edge of the mass had whitish lesions. The bilateral vocal fold was mobile on phonation and inspiration. A chest radiograph showed normal findings.

The provisional diagnosis was glottic carcinoma, based on the patient's age, symptoms, smoking habit, and the irregular appearance of the masses. The patient therefore underwent endolaryngeal microsurgery with a type I cordectomy (subepithelial excision of the mass) under general anesthesia with a diagnostic and curative intent. Intraoperatively, the masses at the middle third of the vocal fold were not adherent to the vocal ligament and did not involve the anterior commissure [Figure 1].

*Corresponding author: ✉marinamatbaki@ppukm.ukm.edu.my

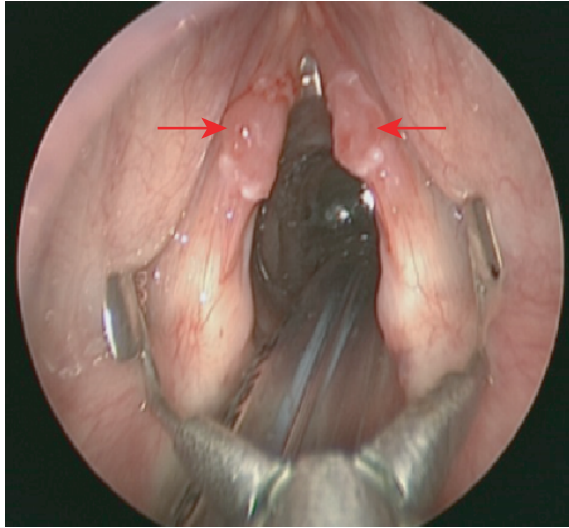


Figure 1: A direct laryngoscopy view showing pinkish, irregular surface lesion arising from the middle third of bilateral vocal folds (arrows). An endotracheal tube is seen posteriorly.

Histopathological examination (HPE) showed lobular proliferation of small capillary-sized blood vessels, lined by endothelial cells that were positive for CD31 and containing red blood cells [Figure 2]. Contrary to the initial diagnosis, HPE revealed no evidence of malignancy. Hence, a diagnosis was made of bilateral vocal fold lobular capillary hemangioma (LCH). At 10 months post-surgery, the patient's voice improved, with overall dysphonia of grade 1 (G1, mild hoarseness), mild roughness (R1), and an

MPT within the normal range (15 seconds). A repeat flexible endoscopy of the larynx showed mobile vocal folds with normal mucosa.

DISCUSSION

Benign tumors of the larynx are rare. Overall, 95% are papillomas, the remaining 5% comprising chondroma, rhabdomyosarcoma, neurofibroma, paraganglioma, hemangioma, etc.⁷ Laryngeal hemangioma is truly rare, especially in adults, with unknown incidence due to scarce literature.¹ Adult laryngeal hemangioma usually occurs in men (60%) mostly in the supraglottis and glottis, and occasionally in the subglottis and trachea.^{1,5,7-9} The clinical presentations vary depending on the location and size of hemangioma. Hoarseness is the most reported symptom, followed by dyspnea, dysphagia and, rarely, hemoptysis.

Our patient presented with chronic progressive hoarseness, dyspnea, and persistent dry cough, common to many laryngeal pathologies such as laryngeal TB, papillomas, hemangiomas, fungal infection, and laryngeal carcinoma.^{7,10-12} Based on the symptoms, endoscopy, and certain predisposing factors, the possible differential diagnoses can be listed. As laryngeal TB can mimic carcinoma, TB work-ups such as erythrocyte sedimentation rate, Mantoux test, and chest x-ray are necessary, especially for those exposed to TB patients.¹²

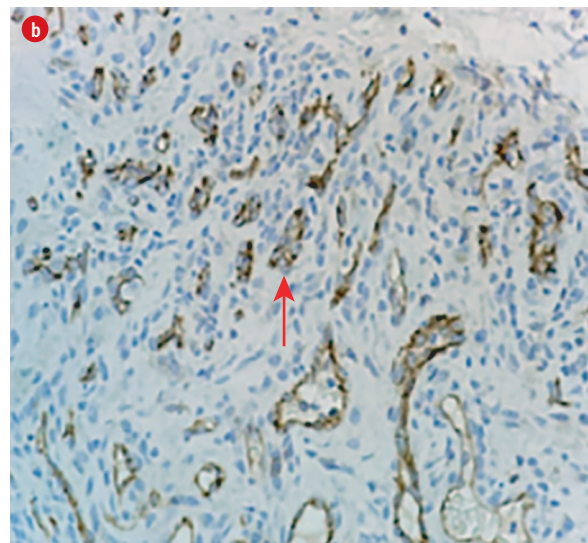
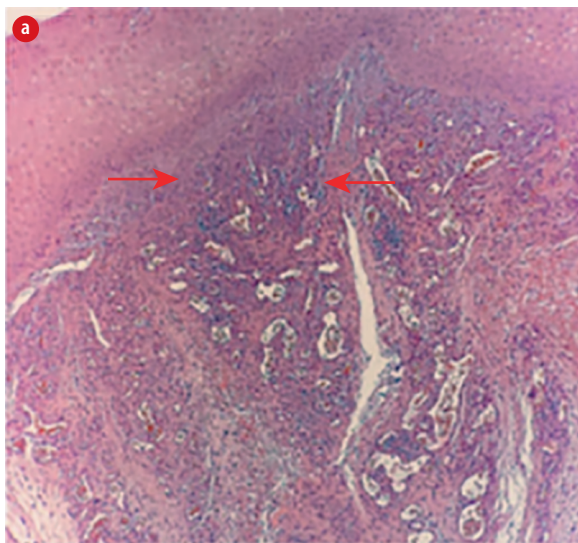


Figure 2: (a) Microscopic view of glottic LCH composed of lobular proliferation of small capillary sized blood vessels (arrows) lined by endothelial cells and containing red blood cells. The overlying epidermis is acanthotic (hematoxylin and eosin stain, magnification = 10 ×). (b) The endothelial cells are positive toward CD31 immunohistochemistry (arrow). (hematoxylin and eosin stain, magnification = 40 ×).

Laryngeal carcinoma is a strong possibility in chronic smokers with irregular, whitish, fungating, or ulcero-fungating laryngeal masses.¹²

Literature describes an adult laryngeal hemangioma as a smooth-surfaced, lobulated or fleshy, reddish to purplish unilateral mass.^{5,9,13,14} However, in the present case, the lesion affected the middle third of the bilateral vocal fold, with an irregular mucosal surface and a whitish lesion at the edge. The absence of the typical features of a hemangioma, the presence of a predisposing factor for malignancy, and the normal chest radiograph findings, led us initially to suspect malignancy.

Computed tomography (CT) of the neck was unnecessary because the masses were small and localised at the true vocal fold, having normal mobility in appearance unlike that of a vascular tumor. In glottic carcinoma, the vocal fold mobility is affected when the paraglottic space, recurrent laryngeal nerve, or cricoarytenoid joint are heavily infiltrated by the tumor, indicating a CT of the neck for staging purposes.¹²

Apart from the adult and infantile forms, laryngeal hemangioma can be further classified into three histological types: cavernous (common in adults), capillary (mostly in infants), and mixed.^{7,15} LCH, also known as pyogenic granuloma, is a benign vascular lesion of skin and mucosa that commonly occurs in the head and neck region. Laryngeal LCH is uncommon and is usually prevalent in children, predominantly in the subglottic region.¹⁶⁻¹⁸ Glottic LCH in adults is extremely rare and, to our knowledge, no case of bilateral glottic LCH has been reported, either in adults or in children.^{2,16-18} Glottic LCH has been described as multilobulated, polypoidal, pedunculated mass or raised nodule.^{2,16-18} Diagnosis of LCH is made histologically by its distinct lobular growth pattern of capillary proliferation, fibromyxoid stroma and ulceration-based inflammation.

A literature review on adult and pediatric glottic LCH revealed cases of successful endolaryngeal surgical excision using cold instruments, a coblator or a CO₂ laser.¹⁶⁻¹⁸ Alternative treatments included intralesional steroid injection and medical therapy, such as proton pump inhibitors, steroids, antibiotics and speech therapy—but giving best results when combined with surgery.¹⁶⁻¹⁸ The alternative treatments by themselves are less invasive, but they require multiple sessions or long term therapy to

achieve a cure. Thus, they may not be suitable for large LCH masses with airway obstruction.

Laryngeal biopsy using a channeled flexible laryngoscope under local anesthesia is feasible in a cooperative patient with glottic fungating mass. We did not adopt this procedure because the glottic masses appeared superficial and biopsy under local anesthesia risked injury to the lamina propria of the vocal fold. Therefore, endolaryngeal subepithelial excision (type 1 cordectomy) of the bilateral glottic masses was executed using a direct laryngoscope, cold instruments, and a microscope. This procedure achieved the dual objectives of diagnostics and curative therapy. This precision surgical technique preserves the layers of the vocal fold and prevents injury to the lamina propria, thereby avoiding the risk of life-long hoarseness due to vocal fold scarring.

CONCLUSION

To the best of our knowledge, this is the first recorded case of adult bilateral glottic LCH, an extremely rare benign lesion of the larynx with an atypical appearance that mimics glottic carcinoma. Endolaryngeal microsurgery with subepithelial excision is a surgical option that serves both diagnostic and therapeutic purposes.

Disclosure

The authors report no conflicts of interest. The patient consented to the publication of this case report for educational purposes.

Acknowledgements

We thank Prof. Tan Geok Chin, Consultant Pathologist from Department of Pathology, Universiti Kebangsaan Malaysia Medical Centre, Kuala Lumpur for providing the histopathological image, immunohistochemistry staining, and his valuable advice.

REFERENCES

1. Akhtar S, Shamim AA, Ghaffar S, Ahmed MS, Ikram M. Adult laryngeal hemangioma; a rare entity. *J Pak Med Assoc* 2012 Feb;62(2):173-174.
2. Fechner RE, Cooper PH, Mills SE. Pyogenic granuloma of the larynx and trachea. A causal and pathologic misnomer for granulation tissue. *Arch Otolaryngol* 1981 Jan;107(1):30-32.
3. Wuyts FL, De Bodt MS, Molenberghs G, Remacle M, Heylen L, Millet B, et al. The dysphonia severity index: an objective measure of vocal quality based on a multiparameter approach. *J Speech Lang Hear Res* 2000 Jun;43(3):796-809.
4. Al Washahi MK, Al Killidar A, Razek YA, Khamis T. Endonasal endoscopic complete excision of unilateral nasal hemangioma in a child: case report and technical note. *Oman Med J* 2019 Mar;34(2):156-159.
5. Salahuddin NA, Hitam S, Hassan NE, Azman M,

- Abdullah MA. Glottic hemangioma a rare entity in adult. *Rawal Med J* 2017;42(1):130-132.
6. Hirano M. Clinical examination of voice. *Disord Hum Commun* 1981;5:1-99.
 7. Grant DG, Birchall MA, Bradley PJ. Surgery for benign tumours of the adult larynx. In: Remacle M, Eckel HE, editors. *Surgery of larynx and trachea*. Berlin, Heidelberg: Springer Berlin Heidelberg; 2009. p. 91-111.
 8. Xu Q, Yin X, Sutedjo J, Sun J, Jiang L, Lu L. Lobular capillary hemangioma of the trachea. *Arch Iran Med* 2015 Feb;18(2):127-129.
 9. İriz AY, Durmaz E, Akmansu H, Dağlı M, Albayrak L, Eryılmaz A. Vocal cord hemangioma; a rare localization in adults. *Turk J Med Sci* 2009 Apr;39(2):305-307.
 10. Ulkumen B, Sert K, Isisag A. Primary laryngeal tuberculosis presenting as a laryngeal carcinoma. *J Clin Case Rep* 2014;4(393):2.
 11. Mäkitie AA, Bäck L, Aaltonen L-M, Leivo I, Valtonen M. Fungal infection of the epiglottis simulating a clinical malignancy. *Arch Otolaryngol Head Neck Surg* 2003 Jan;129(1):124-126.
 12. Marioni G, Marchese-Ragona R, Cartei G, Marchese F, Staffieri A. Current opinion in diagnosis and treatment of laryngeal carcinoma. *Cancer Treat Rev* 2006 Nov;32(7):504-515.
 13. Yilmaz MD, Aktepe F, Altuntaş A. Cavernous hemangioma of the left vocal cord. *Eur Arch Otorhinolaryngol* 2004 Jul;261(6):310-311.
 14. Prasad SC, Prasad KC, Bhat J. Vocal cord hemangioma. *Med J Malaysia* 2008 Dec;63(5):419-420.
 15. Shirazi N, Bist SS, Selvi TN, Harsh M. Spectrum of sinonasal tumours: a 10-year experience at a tertiary care hospital in North India. *Oman Med J* 2015 Nov;30(6):435-440.
 16. Ozturk B, Gunduz FK, Altun E. Lobular capillary hemangioma of vocal cord in an adult. *Surg Oncol* 2018;3:1966.
 17. Egilmez O, Uzun L, Ozkanli S, Kalcioğlu M, Tekin M. A troublesome lesion of the larynx: lobular capillary hemangioma. *Scr Sci Med* 2015 Dec;47(4):56-60.
 18. Walner DL, Parker NP, Kim OS, Angeles RM, Stich DD. Lobular capillary hemangioma of the neonatal larynx. *Arch Otolaryngol Head Neck Surg* 2008 Mar;134(3):272-277.